KUMSA

جمعية طلبة الطب الكويتية

Kuwait Medical Student Association

DISSECT ME
REPRODUCTIVE MODULE

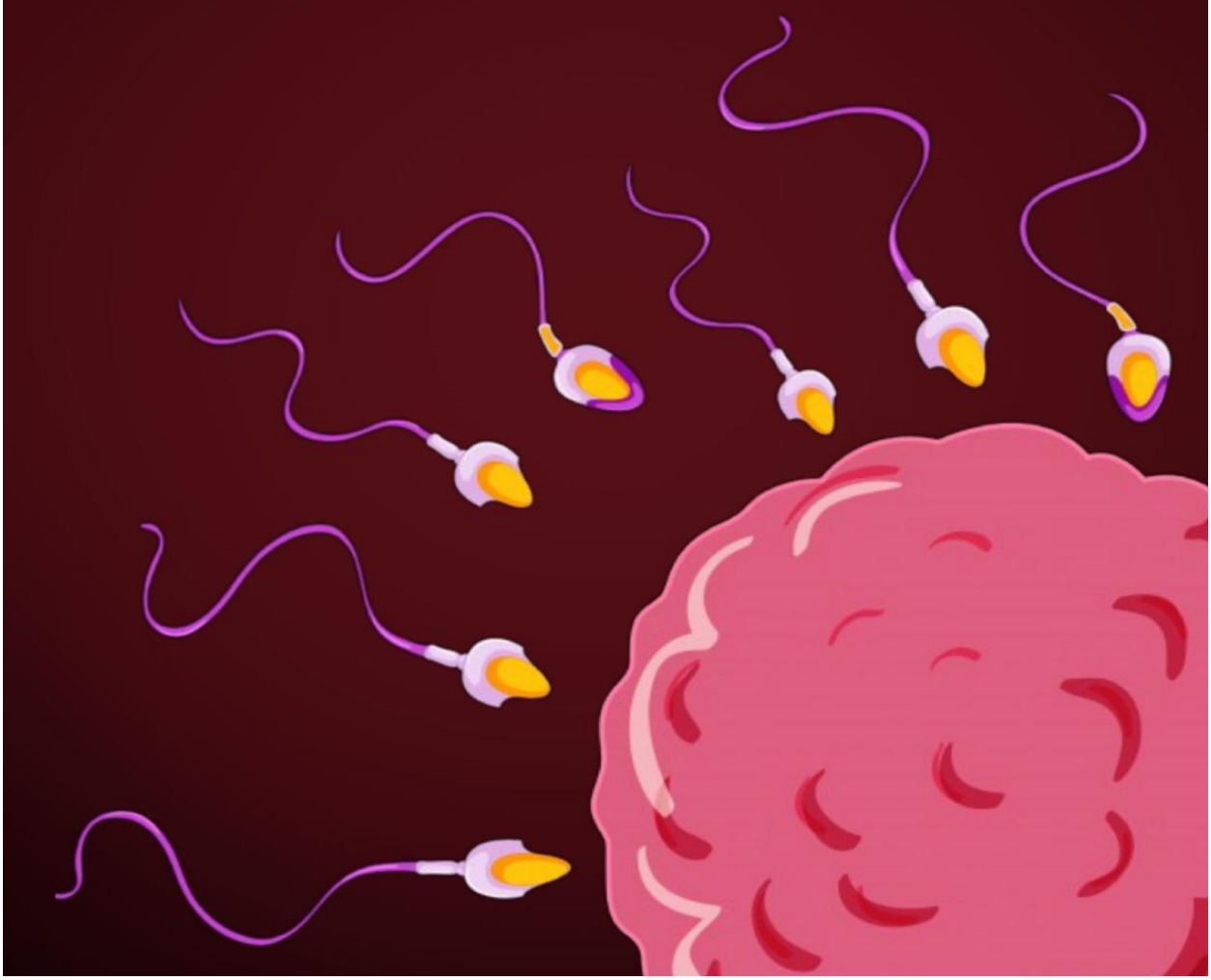

Done by:
Abdullah Alnajem
Ali Ismail
Abdulaziz Alhammad
Ahmed Alshammasi

L1: Development of Male Genital Organs

Sex Differentiation (after fertilization):

1. Chromosomal sex (genetic): TDF on the short arm of the Y chromosome, aka sex-determining region of Y chromosome (SRY-gene) + Autosomal SOX9
2. Gonadal Sex (7th week): germ cells arrive at the genital ridge & transforms into either testes or ovary.
3. After that phenotypic sex (which appears at about 3rd month of fetal life, development of sex ducts and external appearance of sex characters)

Intraembryonic mesoderm → Intermediate mesoderm → Nephrogenic cord (or genital ridge)
Genital ridge forms at 5th week it consists of inner medulla and outer cortex.
Male ducts: paired mesonephric ducts (Wolffian ducts)
Female ducts: paired paramesonephric ducts (Mullerian ducts)

Histogenesis of testis:

1. Germ cells (primitive sex cells): they appear later part of 5th week from endodermal cells of dorsal wall of yolk sac (hind gut)
   If they appear in medulla → testis is formed and germ cells form spermatogonia.
   If they appear in cortex → ovary is formed and germ cells form oogonia.
   If they appear in both (cortex + medulla) → ovo-testis is formed and individual will have intersex condition.
2. Supporting cells (sertoli cells) are derived from coelomic epithelium only in presence of TDF).
   a. It inhibits mitosis of primordial germ cells from entering meiosis.
   b. Secretes mullerian regression factor (MRF/MIF/AMH). MRF induces differentiation of leydig cells from mesenchymal cells in the genital ridge.
3. Interstitial cells of Leydig & stroma are derived from mesenchyme of genital ridge. Leydig cells of the fetal testes secrete:
   a. Testosterone: induces the retention of mesonephric duct and promotes its differentiation into duct system of the testes (by 8th week of gestation, Leydig cells begin production of testosterone)
   b. Dihydrotestosterone: essential for the development of male external genitalia (testosterone is converted to DHT with the help of 5a-reductase, if the enzyme is deficient the prostate, penis and scrotum become rudimentary.

At birth interstitial cells degenerate and they reappear only after puberty.
Coelomic epithelium lining genital ridge project inside to form testis cords and they form plexus within genital ridge called rete cords.
Mesenchymal cells of the adjacent mesonephric ridge invade the genital ridge during 7th week of development and forms Tunica albuginea, the septa and mediastinum testis.

Testes cords detached from the surface of genital ridge and form the seminiferous tubules (at puberty)
Cells within the walls of seminiferous tubules form spermatogonia.
Mesonephric tubules → efferent ductules
Mesonephric duct → duct of the epididymis
Mesonephric duct → vas deferens
Rete testis establishes secondary connections with proximal 12-15 mesonephric tubules (efferent ductules of the testis)
MIS paramesonephric ducts in male degenerate except for a small portion in the cranial end
Mesonephric duct → canal of the epididymis vas deferens, seminal vesicle and ejaculatory duct
Appendix of the testis: remnant of degenerated cephalic part of paramesonephric duct
Appendix of the epididymis: degenerated cephalic part of the mesonephros.

Descent of testes:

1. Mesodermal cells within the inguinal fold differentiates and form gubernaculum.
2. Attachments of gubernaculum.
3. Proximally: lower pole of the testis/peritoneal sac/mesonephric duct.
4. Distally: bottom of the scrotum/superficial perineal pouch/symphysis pubis/saphenous opening/anterior superior iliac spine.
5. When testes descend it drags mesonephric duct (future vas deferens), its artery and also peritoneum (processus vaginalis).
6. Testes develop in lumbar region → iliac fossa in the 3rd month → rests at deep inguinal ring up to 7th month → traverses the inguinal canal during the 8th month → at labioscrotal swellings at the end of 8th month.

- Factors for descent of testes: gubernaculum testis/increased intra-abdominal pressure & temperature/uncurling of the fetal curve/secretion of testicular hormone.
- Processus vaginalis (normally) obliterates and remains around testis to form tunica vaginalis.
- If it partly persists → encysted hydrocele of the spermatic cord.
- Totally patent processus vaginalis → indirect/oblique hernia.
- Anorchism: both testes are retained in the abdomen, individual is sterile.
- Monorchism: one testis is intra-abdominal and the other undergoes normal descent.
- Polyorchidism: is the incidence of more than two testes, very rare.
- Cryptorchidism (undescended testes): it occurs 30% in premature males and 3% full term males.
- Descent of testis may fail to occur, or may be incomplete.
- Testis may lie in the lumbar region, in the iliac fossa or in inguinal canal.
- Descent can complete after birth.
- More likely to develop malignant tumor.
- Orchidopexy can surgically correct it.

1. Ectopia testes: abnormal position of testis. After traversing the inguinal canal, testis deviate from normal descent path (testis is usually fully developed). Testis can be in superficial perineal
   pouch/above the penis in front of the pubic symphysis/saphenous opening/anterior superior iliac spine.
2. Hermaphroditism: implies a discrepancy between the gonads & external genitalia
3. True hermaphroditism: ovary on one side and testis on the other side, external genitalia can be male/female (usually ambiguous or predominantly female) 70% are XX
4. Pseudohermaphroditism: gonads and internal genitalia are of one sex while ext. genitalia is of other sex and vice versa.
5. Male pseudohermaphroditism: 46 XY/ Testis are present but external genitalia is female type. Caused by reduced secretion of testosterone & MRF by fetal testes
6. Female pseudohermaphroditism: have 46 XX/ ovaries are present external genitalia is male type caused commonly by congenital adrenal hyperplasia.
7. Testicular feminizing syndrome/androgen insensitivity syndrome: presence of 46 XY, but no androgen receptors MRF → suppresses the development of uterus and uterine tube & the vagina is short & blind → normal breasts but no menstruation

Genital tubercle develops at the cranial end of the urogenital membrane.
Urogenital membrane is bounded on each side by urethral folds (urogenital folds) & further laterally by the raised margin of genital folds (mesodermal cells migrating from primitive streak).
Genital tubercle elongates to form the phallus (under the influence of androgens) which is a precursor of penis (clitoris in females).
During early stages, the genital tubercle is larger in females than in males, which cause misidentification of sex by ultrasound.
Urethral folds fuse to enclose the urethra.
Genital folds fuse to form scrotum.
Genital tubercle + urethral folds + genital folds form under testosterone and MRS/MIS in males.

Genital tubercle + urethral folds + genital folds are influenced by maternal and placental estrogen in females
Hypospadias: incompletes fusion of urethral folds the external orifice becomes at the ventral surface (or undersurface) of the penis.
Epispadia: urethra opens on the dorsal surface close to the anterior abdominal wall.
Rare anomalies: agenesis of penis and urethra/double penis.

L2: Development of Female Genital Organs:

Both males and females, SOX9 and WNT4 are expressed in genital ridge.
Males: expression of SRY upregulates SOX9 → testis differentiation + inhibiting expression of WNT4
Females: WNT4 is not inhibited so it upregulates DAX1 that will inhibit SOX9. WNT4 is the ovary determining gene

- Ovary develops at cortex of genital ridge.
- Germ cells appear beneath the surface epithelium of the genital ridge by migration from the dorsal wall of the hind gut (endoderm).
- Medullary region of genital ridge will be replaced by vascular stroma.
- Gonadal ridge environment controls development of germ cells, but outside they can develop teratomas.
- Second generation of cells (cortical cords) develops from the surface epithelium to cortex which form “follicular cells”.
- Follicular cells & oogonia form primordial follicle.
- All primordial female germ cells appear by end of 5th week.
- Primordial cells multiply and give rise to numerous oogonia.
- At end of 3rd month some oogonia undergo mitosis to form primary oocytes.
- End of 7th month all oogonia stop dividing and are transformed into primary oocytes.
- Primary oocytes enters into prophase stage of the 1st meiotic division.
- Once completed prophase stage it enters a resting stage dictyotene stage until puberty

Descent of ovary:
Ovary goes from posterior abdominal wall descends to pelvic cavity by gubernaculum. The proximal part of the gubernaculum persists as the ovarian ligament & distal part forms the round

ligament of uterus peritoneal pouch extending along the ovary is called canal of Nuck, which usually regresses.

- Epoophoron: Proximal mesonephric tubules connected to ovary
- Paroophoron: Proximal mesonephric tubules not attached
- Gartner's duct: Remnant of the proximal mesonephric duct
- Maternal and placental estrogens are responsible for development of uterus, uterine tubes and stimulate differentiation of female external genitalia
- Ovarian cysts: Developmental arrest of ovarian follicle
- Ovarian teratoma (arising from pluripotent cells) may give rise to bone, cartilage, hair.
- Adrenal & thyroid tissue may also be present in the ovary.

Each paramesonephric duct consists of 3 parts:

1. Upper lies lateral to mesonephric duct and opens in coelomic cavity
2. Middle part is horizontal
3. Lower part lies close to the opposite paramesonephric duct and bulge blindly in the dorsal wall of the urogenital sinus

- In absence of testosterone, the mesonephric ducts in female degenerate.
- Upper & middle part paramesonephric duct forms uterine tube.
- Lower part of the 2 paramesonephric duct fuses to form a common 'utero-vaginal canal'.
- Upper part of the utero-vaginal canal forms the uterus (uterus is entirely mesoderm in origin)
- Lower part of the utero-vaginal canal projects into the dorsal wall of the urogenital sinus. This part of the canal is transformed into a vaginal cord by proliferation of cells from paramesonephric duct.
- Endodermal cells of the urogenital sinus evaginate into lower end of the vaginal cord (Mullerian eminence) forming sino-vaginal bulbs or vaginal plate
- Central cells of the bulb degenerate to form vaginal canal
- Mucous membrane of the vagina above the hymen is developed from endoderm of the canalized sino-vaginal bulb.

Note: mucous lining of the uterus is from mesoderm while vaginal mucous membrane is endoderm.

1. Imperforate hymen: failure disintegration of cells at Mullerian eminence (vaginal cord)
2. Congenital atresia of the vagina: failure of canalization of the sino-vaginal bulb.
3. Congenital recto-vaginal fistula: Mullerian eminence projects into the rectal segment of the cloaca due to incomplete development of urorectal septum.
4. Congenital Vesico-vaginal fistula: Mullerian eminence ruptures in the vesicourethral canal instead of urogenital sinus
5. Uterus Didelphys: double uterus and double vagina, happens due to complete failure of fusion of the 2 paramesonephric ducts
6. Uterus Bicornis: uterus has 2 horns with single vagina, happens due to paramesonephric duct fails to fuse, but lower end forms vaginal plate
7. Bicornuate Uterus with rudimentary horn: Complete or partial atresia of one of the paramesonephric ducts, the rudimentary part lies as an appendage to the well developed side.
8. Septate Uterus: failure in the canalization after fusion of paramesonephric ducts
9. Unicornuate Uterus: unilateral suppression of paramesonephric duct.
10. Turner syndrome: 45XO - female phenotype with streak gonads - complete deletion of one X chromosome - the remaining X is maternal in origin (75%).
11. Klinefelter syndrome: 47XXY - infertility gynecomastia - nondisjunction of XX homologues most common cause.
12. XYY Chromosomes: phenotypically normal male - paternal nondisjunction at meiosis I leading to sperm with extra chromosome - increased risk of learning disabilities - often several cm taller than parents and siblings.

13. 5a reductase deficiency: Testes present but external genitalia are female type or ambiguous internal genitalia are male because of testosterone and MIS.
14. Gonadal Dysgenesis: oocytes are absent ovaries appear as streak gonads - phenotypically female but may have variety of chromosomal complements.
15. XY Female Gonadal Dysgenesis (Sawyer Syndrome): point mutation OR deletion of SRY gene - appears to be female but no menstruation + no secondary sex characteristics at puberty.
16. Fragile X syndrome: genetic condition changes in long arm of X chromosome - most common form of inherited intellectual disability (mental retardation) in boys - characterized high forehead, large ears, long face, and large testis - change in FMR1 small part of gene code is repeated on a fragile area of X chromosome - FMR1 makes protein for brain growth - males are affected more.

L3: Male Reproductive System

Testes and scrotum:

- Position: suspended in scrotum by spermatic cord covered by scrotal layers (internal spermatic fascia → cremasteric muscle and fascia → external spermatic fascia → dartos muscle → skin (NO FAT)
- Sperm can't be produced at body temp. 37°C → testes are in scrotum which is about 3°C cooler
- Testicular thermoregulation:

a. Cold temperature – dartos muscle contract, making skin wrinkles and brought close to testes
b. Warm temperature – dartos relaxes and testes descends deeply into scrotum, helping dissipation of heat
c. Plexuses of veins around testicular artery for countercurrent heat exchange

- Cremaster reflex: stroking medial side of thigh result in elevation of testis and scrotum by cremaster muscle (by L1 & L2) in children.
    a. Afferent: ilioinguinal nerve (L1 and L2)
    b. Efferent – genitofemoral nerve (L1 and L2)
- Lymphatic drainage of scrotum: superficial inguinal lymph nodes
- Nerve supply to scrotum:
    a. Anterior 1/3rd – L1 ilioinguinal (medially) and genitofemoral nerves (laterally)
    b. Posterior 1/3rd – S3 posterior scrotal and perineal branch of posterior cutaneous nerve of thigh
- External features of testes:
    a. 2 poles – upper pole is overlapped by head of epididymis and connected to it by efferent ductules
    b. 2 borders – posterior border is related to body of epididymis on posterolateral aspect and vas deferens on posteromedial aspect
    c. 2 surfaces – lateral surface is separated from epididymis by a recess called sinus of the epididymis (part of tunica vaginalis)
- Covering of testis (from outside inwards)
    a. Tunica vaginalis – covers testes except posterior border. It have 2 layers with a cavity between them called sinus of epididymis
    b. Tunica albuginea – thick fibrous membrane, forms mediastinum testis, number of fibrous septa arising from this mediastinum divides testes into lobules, each lobule is occupied by seminiferous tubules and leydig cells
        - Leydig cells secretes testosterone.
        - Seminiferous tubules at apices of lobules become straight lobules and enters mediastinum to form rete testis.
        - Tunica vasculosa – vascular membrane.
- Blood supply to testes: testicular arteries and pampiniform plexus of veins (testicular veins). Varicose veins (bag of worms) is more common on left side
- Lymphatics of testes: preaortic lymph nodes
- Nerve supply to testes: vagal parasympathetic & T10-11 segment of spinal cord is sympathetic (afferent) therefore referred pain to umbilicus as it is also supplied by T10
- If patient have scrotal cancer = enlarged superficial inguinal lymph node
- If patient have testicular cancer = enlarged preaortic lymph node

Epididymis:

- First part of efferent route from testis
- Stores sperms in their last stage of maturation
- The cells lining the ductus reabsorbs 90% of testicular secretion
- Parts: head, body, and tail

- Tail continues as vas deferens

Spermatic cord:

- From deep inguinal ring to upper pole of **testis**
- Normal constituents: vas deferens, testicular artery, artery to vas, pampiniform plexus, genitofemoral nerve and autonomic nerves
- Abnormal constituents: accessory suprarenal cortical tissue, accessory spleen, and remnant of processus vaginalis
- Covering of spermatic cord: internal spermatic fascia → cremasteric fascia and muscle → external spermatic fascia
- Torsion of it obstructs venous drainage causing edema, hemorrhage and subsequent arterial obstruction, also lead to necrosis of the germ cells
- What nerve runs parallel to spermatic cord in the inguinal canal? Ilioinguinal nerve

Vas deferens:

- Course: ascend posterior to testes → inguinal canal → **crosses external iliac vessels** to enter pelvis → descend in lateral wall of pelvis → proceed forward in pelvic floor → crosses the ureter
  superficially from lateral to medial side → descend on base of prostate to join duct of seminal vesicle to form ejaculatory duct, which opens in prostatic urethra.
- Vasectomy: bilateral ligation/excision of vas deferens. The ejaculated fluid has secretion of prostate and seminal vesicle but doesn't contain sperms

Prostate:

- Activity begins during puberty
- Under influence of testosterone
- Secretion is rich in acid phosphatase
- Produces prostate-specific antigen (PSA), a serine protease that liquefies semen after ejaculation
- Location: in lesser pelvis below neck of bladder, behind lower border of pubic symphysis
- Coverings: no true capsule but enclosed visceral fascia
  - outer false capsule derived from endopelvic fascia, which is thickened to form supporting ligaments of prostate and bladder.
- Structures traversing prostate: prostatic urethra and right and left ejaculatory duct
- **Parts and relations:**
  - Apex - related to external urethral sphincter
  - Base – pierced by urethra
  - Anterior surface – posterior to pubic symphysis, separated by retropubic space that is filled with fat and dorsal venous plexus
  - Right and left inferolateral surfaces – in contact with levator ani muscle (pubourethralis)
  - Posterior surface – pierced by right and left ejaculatory ducts, separated from rectum by rectovesical fascia of denovillier
  - About 4 cm above anus and can be felt in rectal examination
- **Lobes of prostate:**
  - Anterior lobe – devoid of glandular tissue
  - Posterior lobe – abundant amount of glandular tissue (primary site of carcinoma)
  - Lateral lobe – also many glands

- Median love – projects into trigone of bladder (projection called uvula vesicae), mainly fibro-muscular (hence benign prostatic hypertrophy is common in median lobe), if enlarged can obstruct the outlet of bladder

- **Zonal anatomy:**
  - Outer peripheral zone (70% of prostatic tissue) – prone to carcinoma
  - Central zone (25%) – surrounds ejaculatory duct and occupies posterior to upper prostatic urethra
  - Transitional zone (5%) – BPH is more common here

- **Blood supply**: inferior vesical, middle rectal, and internal pudendal arteries
- **Veins:** form a prostatic plexus, communicate with vesical venous plexus and drains into internal iliac vein through posterior ligaments of prostate.
- Also drain into internal vertebral venous plexus (Batson plexus) thus prostate cancer can metastasize to vertebral column.
- **Lymphatic drainage:** internal iliac, sacral, external iliac group of lymph nodes.
- **Nerve supply:**
  - Sympathetic from L1-2 through superior hypogastric plexus – for smooth muscles of prostate and ejaculation, and motor to internal urethral sphincter.
  - Parasympathetic from pelvic splanchnic nerve S2-4 – cavernous nerve innervates erectile tissue for penile erection.

Benign prostatic hypertrophy (BPH)

- Proliferation of fibromuscular stroma and epithelial cells of prostate
- Compress urethra and obstruct urinary outflow
- More strain leads to more occlusion of urethra
- Causes nocturia, dysuria, and urgency
- Confirmed by rectal examination
- Terazosin and other alpha-blockers are first-line treatment of BPH
- Transurethral resection of prostate (TURP) can also be done

Seminal vesicle:

- Blood supply: branches of inferior vesical and middle rectal arteries
- Secretion is rich in fructose, prostaglandin, and alkaline phosphatase
- Alkaline phosphatase to neutralize acidity of vagina

Bulbourethral gland:

- Location: deep perineal pouch on each side of membranous urethra
- Surrounded by external urethral sphincter
- Ducts of gland opens into spongy urethra

Penis:

- Male organ of copulation
- Made up of root and body
- Root of penis: in superficial perineal pouch, and composed of 2 crura and 1 bulb
  - Each crus is covered by ischiocaverosus, and each is pierced by deep artery of penis
  - Bulb is coverd by bulbospongiosus, and its deep surface is pierced by urethra and artery to bulb on each side of urethra

- Body of penis: free portion of penis, completely enveloped by skin, composed of right and left corpora cavernosa (continuation of crura) and corpus spongiosum (continuation of bulb)
    - During erection, these are engorged with blood, leading to enlargement
    - Terminal part of corpus spongiosum is expanded to form glans penis
    - Base of glans penis has corona glandis, which contains numerous small preputial glands that secrete a sebaceous material called smegma
- **Blood supply:** many arteries derived from internal pudendal artery. Under stimulus of parasympathetic pelvic splanchnic nerve, there is vasodilation in the cavernous tissue → compressing the veins preventing outflow of blood → erection
- **Nerve supply**: skin, prepuce, and glans by dorsal nerve of penis (branch of pudendal nerve). Parasympathetic pelvic splanchnic nerve and sympathetic fibers from L1
- **Lymphatic drainage**: skin and prepuce by superficial inguinal, gland by deep inguinal lymph nodes, deeper tissues by internal iliac nodes
- Penile fracture is an injury to tunica albuginea → subcutaneous hematoma
    - Caused by erect penis or blunt trauma
    - Less commonly present with swelling within scrotum, suprapubic region, and perineum secondary to hematoma extravasation outside of Buck's fascia

L4: The Female Reproductive System

Parts: internal genitalia & external genitalia

- Internal: 2 ovaries, 2 uterine tubes (fallopian tube) and a uterus
- External: Labia major/minora, clitoris, greater vestibular gland & vagina

Parts and relations of the uterus:

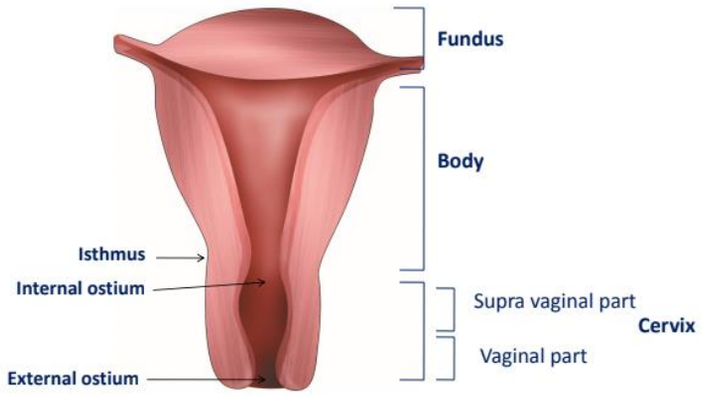

Note: the cervix protrudes into the vagina therefore it is divided into a supra-vaginal and vaginal part.

- Anteriorly related to the urinary bladder and the rectum posteriorly.
- Laterally connected to the pelvic wall by the broad ligament. (peritoneal ligament)
- Peritoneum from anterior surface of the rectum reflects to posterior fornix of the vagina then covers the uterus forming the rectouterine/ Douglas pouch (related to sigmoid colon) which

is the most dependent part of the female pelvis & fluid tends to accumulate in this space, which can be drained through posterior fornix of the vagina.

- Peritoneal pouch between bladder & uterus is uterovesical pouch/vesicouterine pouch
- Enlargement of uterus, uterine tubes and ovary can be felt in Douglas pouch during digital rectal examination. (after the first delivery the ovaries usually occupy this pouch instead of the ovarian fossa)
- The normal axis of the uterus is 90° angle of anteversion (angle of cervix to vagina) & Angle of anteflexion 125° (angle of cervix to uterus).
- These angles are important as they provide stability to uterus.
- Any backward tilt in this angle is called retroversion (retroverted uterus). A retroverted uterus comes in line with the axis of the vagina and may lead to prolapse of uterus. Retroverted Uterus can cause prolapse of uterus/painful menstruation/reduce the chance of conception.
- If uterus presents backward angulation between cervix and vagina, it is called 'retroflexed uterus'.
- Lateral border of the cervix provides attachments to broad ligament of the uterus
- The uterine tube opens at the supero-lateral angle of the uterus which provides attachment to round ligament of uterus and ovarian ligament. (both from the gubernaculum)

Uterine blood supply:

- The uterine artery ascends between the two layers of broad ligament crossing the ureter lateral to the cervix and later anastomoses with the ovarian artery which came from/ through the suspensory ligament of the ovary.
- The cervix is the most fixed part of the uterus and has Simple columnar epithelium gradually changing to stratified squamous epithelium towards the vagina
- Ligaments of the cervix are Mackenrodt's lig, Uterosacral & Pubocervical ligaments which are condensations of the pelvic fascia.
- The lymphatic drainage is v. important for the prognosis of cervical cancer; on both sides of the cervices lies a paracervical lymph node close to the ureters. Mainly the cervix drains to external iliac nodes. Involvement of external iliac group can interfere with lymphatic drainage of the lower limb causing edema in the lower limb. (cervical cancer can cause hydroureter and hydronephrosis by compressing the ureter)

Uterine nerve supply:

- Sympathetic – derived from T12 to L1 segment of the spinal cord.
- Parasympathetic - derived from pelvic splanchnic nerve (S2, 3 & 4).

Clinical significance: The pain fibers from fundus and body is conveyed through sympathetic nerves (T12 to L1). The pain fibers from cervix and vagina is conveyed through pelvic splanchnic nerve (S2,3 & 4). Even though most pain is avoided through the pelvic splanchnic nerve block some pain is still felt through the sympathetic nerves. Options of anesthesia include:

- Caudal analgesia: It is an epidural anesthetization through sacral hiatus and bathes S2 to S4 spinal nerve roots. This would anesthetize cervix and upper 3/4th of the vagina. In this procedure, the upper part of the body of the uterus is not affected; hence mother is aware of uterine contraction.
- Pudendal block: anesthetize pelvic floor and perineum but not the cervix and lower vagina. Mother can feel the uterine contraction. The needle is passed through the vagina, the other hand is guided through lateral wall of vagina for feeling the ischial spine. Since fetal head is usually stationed within the lesser pelvis at this stage, it is important that the physician's finger is always positioned between the needle tip and the baby's head during the procedure
- Spinal anesthesia: epidural but higher up so This would anesthetize entire uterus, vagina, perineum and lower limb. The mother is conscious in this procedure. If the

labor is extended and anesthetic fluid is inadequate it is difficult to re-administer anesthesia, as it is heavier than CSF, tend to settle in lower subarachnoid space.

- General anesthesia: This method is used in cases of emergency. The mother is unconscious, unaware of labor & delivery. She is also unaware of earliest moments of her baby's life. The child birth occurs passively with maternal hormones.

Supports to the uterus & vagina:

- Pelvic diaphragm & perineal body**.**
- The diaphragm forms the Pubovaginalis part of the levator ani. It forms a sling around the vagina acting as a sphincter. Damage to these muscle fibers during vaginal delivery can eventually cause prolapse of uterus).
- If the perineal body is torn during vaginal delivery or during episiotomy and not properly repaired, it can cause prolapse of the uterus.)
- Damage to either can also lead to urinary incontinence as it disturbs the position of the neck of the bladder, which is characterized by dribbling of urine when intra-abdominal pressure is raised during coughing and lifting. Perineal exercise (Kegel's exercise) to maintain a good tone of the pelvic diaphragm is suggested in pregnant women.
- The axis of the uterus: The axis of uterus is an important mechanical factor stabilizing the uterus. The round ligaments of the uterus tend to pull the fundus forward and uterosacral ligaments tend to pull the cervix backwards. These ligaments maintain the normal axis of the uterus. A retroverted uterus can prolapse through the vagina.

The condensations of the pelvic fascia:

- Pubocervical ligament: from the anterior aspect of the cervix to posterior surface of the pubis
- Transverse cervical ligament (Meckenrodt's ligament). It extends from lateral aspect of the cervix to the lateral pelvic wall. The uterine arteries reach the uterus through this ligament.
- Uterosacral ligament: from posterior aspect of the cervix to 3rd piece of the sacrum. It pulls the cervix backward and helps to maintain the normal axis of the uterus.
- Round ligament of uterus: pulls the fundus forward maintaining the axis (it exits the pelvis via the deep inguinal ring, passes through the inguinal canal and continues on to the labia majora where its fibers spread and mix with the tissue.

Broad ligament of the uterus:

- Double layered peritoneal fold extends from the lateral border of the uterus to lateral pelvic wall.
- Encloses the uterine tube in its medial 3/4th and lateral 1/4th form the suspensory ligament of the ovary for the passage of ovarian vessels.
- base is attached to the pelvic floor where the two layers move apart. It is related to transverse cervical ligament and uterine vessels.
- The posterior layer of the broad ligament extends towards ovary as a double layered fold called 'mesovarium
- Contents: uterine tube, Uterine vessels and ovarian vessels, Round ligament of the uterus and ligament of the ovary & Lymphatic and nerve fibers
- Mesosalpinx - portion between the uterine tube and ovarian ligament
- Mesometrium – portion below the ovarian ligament

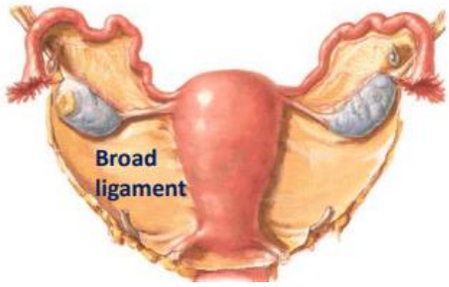

Parts & relations of the ovary & uterine tubes:

- Ovary: situated in the ovarian fossa on the lateral pelvic wall (remember might move after first baby)
- During pregnancy, the ovary rises to the abdominal cavity and after parturition it returns to the pelvic cavity and can occupy recto-uterine pouch.
- Though the normal ovaries are not palpable, enlarged ovaries and ovaries in recto-uterine pouch are palpable by vaginal examination.
- Upper end (tubal end) - uterine tube & suspensory ligament of the ovary
- Lower end (uterine end) is connected with supero-lateral angle of the uterus by the ligament of ovary
- Anterior border - connected to the posterior layer of broad ligament by a peritoneal fold called 'mesovarium'. The ovarian vessels and nerves enter the ovary through it. This is also referred as white line of the ovary and hilum of the ovary. Anteriorly it is related to external iliac vessels.
- **Clinical significance: A long mesovarium or suspensory ligament of the ovary can cause torsion of the ovary. Ovarian torsion is compresses the blood vessels and cause severe abdominal pain**

Arterial supply to ovary

- Ovarian artery: branch from the abdominal aorta, enters the suspensory ligament of the ovary, then broad ligament and finally reach ovary through mesovarium. (Also Through anastomosis with the uterine artery it also supplies uterine tube and uterus.)
- Branches from uterine artery

Venous drainage of ovary:

- The ovarian veins follow the ovarian artery and drains into inferior vena cava on the right side and left renal vein on the left side.

Lymphatic drainage of ovary:

- The lymph vessels accompany the blood vessels and drain into pre and para aortic group of lymph nodes.

Nerve supply of ovary:

- The sympathetic fibers are derived from T10 to T12 segment of the spinal cord, which carry pain sensation from the ovary. Hence ovarian pain is felt at pubic and lower abdominal region.

Blood supply to the uterine tube:

- Uterine tube is supplied by branches of uterine and ovarian arteries. The venous blood is drained into uterine and ovarian veins
- Nerve supply to the uterine tube:
  - The sympathetic is derived from T10 to L2 segment of the spinal cord.
  - The parasympathetic fibers are derived from both vagus and pelvic splanchnic nerves.

Tubal pregnancy (ectopic pregnancy): An ectopic pregnancy results when a blastocyst implants outside the lumen of the uterus. Occurs in the uterine tube (95% to 97%), in the ampulla (the usual site of fertilization and widest portion), or the isthmus (the narrowest portion). Histories of a pelvic infection (pelvic inflammatory disease) is a risk factor, tubal ectopic pregnancies will usually rupture during the first 8 weeks of pregnancy, typically resulting in abortion of the embryo and intra-abdominal bleeding, with resultant hypotension and tachycardia. Tubal pregnancy in the narrow isthmus tends to rupture sooner than those in the ampulla and produce greater hemorrhage than implantation in the ampulla. Blastocysts implanted in the ampulla may be expelled into the

abdominal cavity, where they may re-implant. Ruptured uterine tube requires immediate surgical interference, because it can be a threat to mother's life.

Important clinical procedures

- Hysterectomy: a procedure of surgical removal of the uterus. It is very common operation, performed most often to treat tumors and cancers of the uterus.
- Sites at which ureter is at risk during surgery:
    - While ligating the ovarian vessels within the suspensory ligament of ovary (ureter lies just medial to these vessels)
    - While ligating the uterine artery (ureter crosses the uterine artery inferiorly)
    - The ureters are at risk in a vaginal hysterectomy as they course just laterally to the uterine cervix

Types:

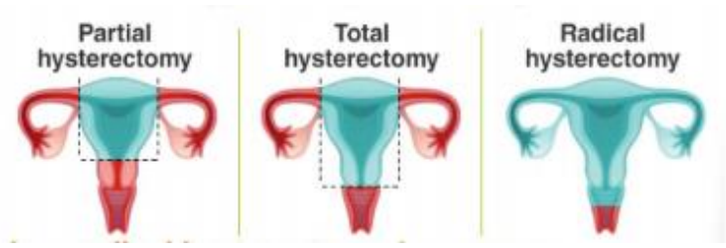

Pap smear: It is a cell/tissue study from the cervical endometrium where a spatula is placed in the uterus. The spatula is rotated to scrape cellular material from the mucosa of the vaginal part of the cervix, followed by insertion of a cytobrush into the cervical canal that is rotated to collect the mucosa from supravaginal part of the cervix. The cellular material is placed on the glass slide and a smear is prepared for cytological studies.

L5: Male & Female Histology

Male: consists of testes, excurrent ducts (urethra, ductus deferens), Accessory sex glands (seminal vesicles, prostate, and bulbourethral glands).
Two functions: sperm and steroid production**.**

Structure of the testis:

- Tunica albugenia: Thick connective tissue.
- Tunica vasculosa: Has blood vessels.
- Incomplete connective tissue septa divide the testis into 250 lobules Each with 1-4 seminiferous tubules with seminiferous stratified epithelium. (sertoli cells and germ (spermatogenic) cells. In between the tubules, the Leydig cells are present)
- Each tubule is highly coiled and becomes straight (straight tubule) near the mediastinum. The straight tubule becomes continuous with the rete testis.
- On the other hand, intra-testicular ducts Lined only by Sertoli cells and are near the end of the straight tubule, the epithelium becomes simple cuboidal. These cells have a single apical cilium and a few microvilli.
- Mediastinum testis: Along the posterior border formed by tunica albuginea. It consists of blood vessels, lymphatics, and excurrent ducts pass through.

Spermatogenic (germ) cells:

- Germ cells are organized into layers in the seminiferous epithelium.
- Most mature cells spermatids and Sperms are attached to the Apical portions of the Sertoli cells & immature germ cells spermatogonia - rests on the basement membrane.
- Tunica (lamina) propria: known as peritubular tissue is a multilayered connective tissue that has peritubular myoid cells (3-5 layers)-contractile cells.
- These cells resemble smooth muscle cells & have actin filaments and rER. Contractions of these cells help sperm to move from the tubules. With age, thickness of tunica propria increases. This process is associated with decrease in sperm production.

Sertoli cells:

- They are the supporting (sustentacular cells). Tall columnar non-dividing cells that rest on basal lamina.
- Germ cells attach to their surface after meiosis.
- Nucleus is euchromatic-ovoid or triangular located either at the base or at the middle.
- They have an elongate mitochondrion, Golgi apparatus.
- Microtubules, lysosomes, lipid droplets, vesicles, sER, rER, annulate lamellae,Glycogen and filaments are also present.
- Sertoli cell nucleus has Karyosome (RNA containing nucleolus + 2 DNA containing bodies).
- Inclusion bodies called Charcot-Bottcher bodies (crystalloid bodies) are present in the basal cytoplasm.
- FSH receptors are there on the Sertoli cell.

Functions of the Sertoli cells:

Secretion of:

1. Fluid
2. Androgen binding protein (ABP).
3. Inhibin-endocrine.

4. Plasminogen activator.
5. Transferrin.

Leydig cells:

- They are present outside the peritubular tissue, between the tubules
- Large, polygonal, eosinophilic cells containing lipid droplets and rod shaped cytoplasmic crystals called crystals of Reinke
- These cells have sER (eosinophilic) and are steroid synthesizing cells. The enzymes necessary for testosterone synthesis are associated with sER.
- Leydig cells secrete testosterone, which is necessary for development of testis, spermatogenesis, accessory gland functions, and normal sexual characteristics.

Excurrent duct system – efferent ductules:

- They are what connect the superior end of the rete testis to the proximal portion of the duct of the epididymis. (total of 20 efferent ductules)
- They are highly coiled and form conical masses-coni vasculosi. and form the head of the epididymis.
- Efferent ductules open into the duct of the epididymis. Lined by pseudostratified columnar epithelium (tall & short cells -saw-toothed appearance).
- Occasional basal cells (stem cells) are seen between tall cells. Tall columnar cells are ciliated while Short cells are non-ciliated, but microvilli are present.
- Efferent ductules absorb the seminiferous tubular fluid.

Epididymis:

- Contains efferent ductules and the duct of the epididymis. It also has smooth muscles, and connective tissue.
- The epididymis is highly coiled and The sperm matures in the duct while it travels through it.
- The sperm head is modified by the addition of surface-associated decapacitation factor which inhibits fertilization.
- In female reproductive tract capacitation takes place (decapacitation factor is removed) so fertility can take place.
- Lined by pseudo-stratified columnar epithelium. •It has principal cells (tall) and basal cells (short).
- Principal cells have numerous long modified microvilli called stereocilia while Basal cells are the stem cells.
- Some intra-epithelial lymphocytes called ‘halo cells’ are present.

Functions of the epididymis:

1. Absorption of fluid-proximal portion.
2. Phagocytosis.
3. Principal cells secrete glycerophosphocholine, sialic acid, and glycoproteins-for sperm maturation.
4. Smooth muscle contractions helps sperm to move.

Ductus Deferens:

- Continuation of the tail of the epididymis. Its lumen is not smooth, because of folding of mucosa. (Outside the mucosa lies the muscle wall.)
- The ductus deferens is lined by a pseudostratified epithelium.
- The smooth muscle layer presents 3 distinct layers- inner and outer longitudinal, and middle circularly arranged fibers.
- At the ampulla, the muscle layer is thinner, because longitudinal layer disappears.
- Tall columnar cells have long microvilli.
- The rounded basal cells rest on the basal lamina.

Accessory sex glands - seminal vesicle:

- Paired, elongate highly folded tubular glands.
- The duct of the seminal vesicle joins with the ductus deferens to form the ejaculatory duct.
- The wall of seminal vesicle contains a mucosa, smooth muscle and a fibrous coat. (Contraction of smooth muscle coat discharges the secretion into the ejaculatory ducts and helps to flush sperm out of urethra.)
- The mucosa is folded into primary, secondary and tertiary folds to increase the surface area and the irregular chambers formed communicate with each other.
- The mucosa is lined by pseudostratified columnar epithelium.
- Has tall non-ciliated cells and short round cells. The short cells rest on basal lamina and act as stem cells.
- The columnar cells are protein secreting cells with rER and large secretory vacuoles.
- Seminal vesicle secretes a whitish yellow, viscous material containing -fructose, other simple sugars, amino acids, ascorbic acid and prostaglandins.
- The functions of seminal vesicle is under the control of testosterone.

Accessory sex glands – prostate:

The prostate has outer capsules, inner fibro -muscular stroma and glandular tissue. (Alveoli contain prostatic concretions (corpora amylacea)

- Epithelium is pseudostratified columnar (may be columnar or simple cuboidal).
- Prostate is testosterone dependent).
- Epithelial cells produce enzymes - acid phosphatase (AP), fibrinolysin, serine protease (PSA) and citric acid and They become components of semen.
- In prostatic cancer, levels of AP and PSA increase, which serve as markers.

Accessory sex glands – bulbourethral glands:

Also called Cowper's glands-located in the urogenital diaphragm. The duct of this gland joins with the penile urethra.

- Glandular tissue is tubulo-alveolar-mucus glands.
- Epithelium is simple columnar-testosterone dependent.
- Secretion is mucus-contains galactose, galactosamine, galacturonic acid, sialic acid, and methylpentose. Serving as a preseminal fluid to lubricate the penile urethra.

Penis:

The penis has 2 dorsal masses of erectile tissue- corpora cavernosa, and a ventral mass of erectile tissue-corpus spongiosum.

- Penile urethra (lined by transitional epithelium) is embedded in corpus spongiosum.
- The corpora cavernosa contain vascular spaces lined with endothelium. Vascular spaces are surrounded by thin layer of smooth muscle, criss-crossing the corpus cavernosum. They form the subendothelial cushions surrounding the vascular spaces.

Female: consists of the ovaries, ovarian follicles (and their stages), uterus, cervix, vagina and fallopian tubes.

<u>The cortex of an ovary:</u>

- On the surface, a single layer of epithelial cells called the germinal epithelium which is continuous with the serosa (peritoneum) of the mesovarium.
- The germinal epithelium covers a dense fibrous connective tissue layer, the tunica albuginea, under which are the primordial follicles.

<u>The medulla of ovary:</u>

- The medulla or medullary region is located in the central portion of the ovary and contains loose connective tissue, a mass of relatively large contorted blood vessels, lymphatic vessels, and nerves without any ovarian follicles.

Ovarian follicles and their stages:
(primordial → primary → late primary → secondary → grafian/mature)

<u>Primordial follicles:</u>

- Each follicle consists of an oocyte surrounded by a single layer of squamous follicular cells
- The nucleus of the oocyte is typically large, but the oocyte itself is so big that the nucleus is often not included in a single histological section.

<u>Primary follicle:</u>

- When a primordial follicle begins the changes leading to the formation of a mature follicle, the layer of squamous follicular cells becomes cuboidal
- In addition, the follicular cells proliferate and become multilayered
- follicle undergoing these early changes is called a primary follicle so an early primary follicle may still be one layered, but it is surrounded by cuboidal cells, and this distinguishes it from the more numerous unilaminar (one layer) primordial follicles that are surrounded by squamous cells.

<u>Late primary follicle:</u>

- Multilayered mass of follicular cells surrounding the oocyte.
- The innermost layer of follicular cells is adjacent to a thick eosinophilic layer of extracellular homogeneous material called the zona pellucida
- At this stage of development, the oocyte has also enlarged slightly. (The entire structure surrounded by the zona pellucida is actually the oocyte.)
- Surrounding the follicles are elongate cells of the highly cellular connective tissue, referred to as stromal cells. These stromal cells later surrounding a secondary follicle

become distinguished into two layers designated the theca interna and the theca externa.

Secondary follicle:

- The oocyte is surrounded by several layers of follicular cells that at this stage are known as granulosa cells
- A cavity called the follicular antrum is seen at this stage filled with fluid
- The stromal cells have changed to form 2 layers called the theca interna and theca externa
- The interna is more cellular and displays characteristics of endocrine (steroid producing) cells.
- Meanwhile the externa is a connective tissue layer and its cells are basically spindle shaped.

Mature (Grafian) follicle:

- Further enlarged and mature secondary follicle

Corpus luteum:

- The granulosa layers (membrana granulosa) become plicated, and the granulosa cells, now transforming into cells of the corpus luteum, are now called granulosa lutein cells.
- The plication of the membrana granulosa begins just before ovulation and continues as the corpus luteum develops. (so the mature follicle starts placating, ovulation happens and the follicle ruptures to release to oocyte and the rest of follicle continues to plicate to form the corpus luteum)
- As the corpus luteum becomes more plicated, the former follicular cavity becomes reduced in size.
- At the same time, blood vessels from the theca of the follicle invade the former cavity and the transforming membrana granulosa cells.
- Cells of the theca interna follow the blood vessels into the outermost depressions of the plicated structure.
- These theca interna cells become transformed into cells of the corpus luteum called theca lutein cells.

Corpus luteum albicans:

- As the corpus luteum is being broken down by macrophages , fibroblasts lay down type I collagen, forming the corpus albicans.
- This process is called “luteolysis".
- The remains of the corpus albicans may persist as a scar on the surface of the ovary.
- The corpus luteum normally grows to about 1.5 centimeters in diameter, reaching this stage of development 7 to 8 days after ovulation.
- Then it begins to involute and eventually loses (if there is no fertilization) and is replaced by connective tissue, and over months is absorbed.

Atretic follicles:

- Follicular atresia is the breakdown of the ovarian follicles, which consist of an oocyte surrounded by granulosa cells and internal and external theca cells.
- It occurs continually throughout a woman's life, as she is born with millions of follicles but will only ovulate around 400 times in her lifetime.
- Typically, around 20 follicles mature each month but only a single follicle is ovulated; the follicle from which the oocyte was released becomes the corpus luteum.

- The rest undergo follicular atresia where the granulosa cells undergo apoptosis. (FSH prevents follicular atresia whereas estrogen stimulates the atresia)

Uterine tube:

- The mucosa has many longitudinal folds which are pronounced in the ampulla. (simple columnar epithelium consists of ciliated cell and nonciliated peg cell)
- Ciliated cells are numerous near ovarian end of the tube
- Peg cells are secretory cells that produce a watery tubal fluid contains normal serum proteins, chloride and potassium ions
- Cilia near ovary beat toward uterus
- Lamina propria composed of loose connective tissue
- Muscularis mucosa consists of poorly defined Inner circular layer and outer longitudinal layer of smooth muscle cells (Muscularis peristaltic movements with the beating of the cilia of epithelium help to propel oocyte to the uterus)
- Serosa is a connective tissue layer lined by a simple squamous epithelium contains blood vessels, and nerves

Uterus (endometrium):

- Endometrium is mucosal lining of uterus composed of a simple columnar epithelium (has ciliated columnar cells and secretory columnar cells)
- Lamina propria composed of dense irregular connective tissue and vessels supports epithelium and houses simple tubular glands (The glands have no ciliated cells)
- Endometrium has 2 zones (Functional layer And a Basal layer)
- Functional layer is a thick superficial layer sloughed off during menstruation and replaced during each menstrual cycle (vascularized by coiled helical arteries that originate from arcuate arteries in stratum vasculare / the layer of smooth muscle fibers in the myometrium)
- Basal layer is a deep narrow layer retained after menstruation whose glandular epithelium and connective tissue element regenerate functional layer. (basal layer supplied by short straight arteries which originate from arcuate arteries in stratum vasculare)

Cervix:

- Cervix is the lower part of uterus that protrudes into vagina and It is lined by mucous secreting simple columnar epithelium, but Part of cervix in upper vagina has stratified squamous nonkeratinized epithelium.
- Has a Lamina propria composed of mostly dense connective tissue and many elastic fibers and a few smooth muscle cells
- Mucosa do not slough off during menstruation
- Cervical mucosa contains branched cervical glands (At time of ovulation cervical glands secrete a serous fluid and at other times the secretion become viscous like during pregnancy forming a plug.
- Softening of cervix during parturition (child birth) is due to lysis of collagen.

Vagina:

- A thick stratified squamous nonkeratinized epithelium lines the vaginal mucosa
- Estrogen stimulates epithelium to synthesize glycogen

- Mucosa has no glands but increment of fluid during sexual arousal is due to transudate from vessels of lamina propria and secretion of cervical glands
- Underlying lamina propria composed of loose connective tissue that highly vascularized with many elastic fibers
- Muscular layer of circular and a prominent longitudinal smooth muscle fibers.
- Adventitia consists of dense irregular connective tissue with elastic fibers, many vessels and vast venous plexus and nerves

L6: Anatomy of the Pelvis

Pelvic diaphragm

- Partition between pelvis and perineum
- Made from two muscles:
    - Levator ani (made from two parts):
        - Pubococcygeus
        - Iliococcygeus
    - Coccygeus (aka Ischiococcygeus)
- Levator ani is supplied by 4th sacral nerve and perineal branch of pudendal nerve (S2, 3, 4)
- Tendinous arch of obturator internus
- 3 apertures in females:
    - Urethra (most anterior)
    - Vagina
    - Rectum (most posterior)
- 2 apertures in males
    - **Urethra**
    - **Rectum**

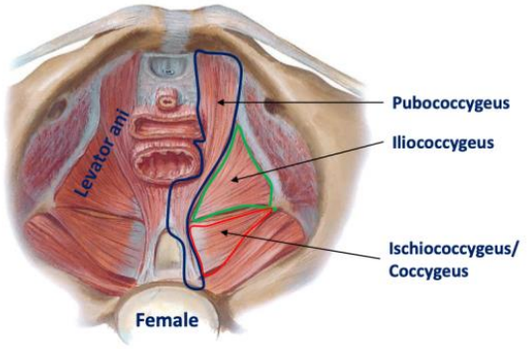

- Puborectalis
    - Maintain angle between rectum and anal canal
    - Important for rectal continence
- Pubovaginalis and vesicalis
    - Prevent prolapse of uterus through vagina
- The pelvic diaphragm prevents the prolapse of pelvic organs during increased intrabdominal pressure
- Injury to anterior levator ani fibres during delivery
    - Prolapse of uterus
    - Prolapse of bladder
    - Urinary incontinence
- Kegel's exercise can maintain tone of pelvic diaphragm in pregnant women
- Pelvimetry: used to determine if vaginal delivery is feasible
- Pelvic inlet:
    - Anteroposterior measurements

        - Anatomical conjugate (12cm): From upper margin of pubic symphysis to promontory
        - Obstetrical conjugate (11.5cm): From posterior surface of the symphysis to promontor
        - Diagonal conjugate (13cm): From inferior pubic ligament to promontor. Measured by digital exam.
    - An obstetrical conjugate less than 10 cm and or the transverse diameter of pelvic outlet less than 8.5 cm may cause difficulties during vaginal delivery.
    - Transverse diameter: 13.5cm
- Pelvic outlet
    - Boundaries
        - Anterior: pubic symphysis
        - Posterior: coccyx
        - Lateral: ischial tuberosities
    - Anteroposterior diameter: 12.5 cm
    - Transverse diameter: 10 cm

Female pelvis types:

1. **Gynecoid**
    - Circular inlet
    - Best chance of normal vaginal delivery
2. **Android**
    - Heart shaped
    - Angle of pubic arch less than 90
3. **Anthropoid**
    - AP diameter longer than transverse

4. Platypelloid

- Kidney shaped
- Transverse diameter greater than AP
- Associated with vitamin D deficiency and osteomalacia

<u>Nerves of the pelvis:</u>

- Sacral plexus
- L4, L5, S1, S2, S3
- Descend toward greater sciatic foramen in front of periformis
- Disease of rectum produces severe pain in lower limbs due to the close proximity of the plexus
- Pelvic splanchnic nerves
- S2, S3, S4
- Parasympathetic supply of pelvic organs
- End by joining inferior hypogastric plexus
- Carry pain from cervix, uterus, and urinary bladder
- Pain from other pelvic organs is carried by SNS

<u>Vessels of the pelvis:</u>

There are multiple vessels from the anterior and posterior branches of the internal iliac arteries, listed here are the most important

Posterior branch:
- Superior gluteal artery
- Passes between lumbosacral trunk and ventral ramus of S1
- Passes through greater sciatic foramen

Anterior branch:
- Superior vesical artery
    - Attached to medial umbilical ligament (obliterated umbilical artery)
- Inferior gluteal artery
    - Passes below S1
    - Enters perineum via lesser sciatic foramen
- Internal pudendal artery
    - Enters perineum via lesser sciatic foramen
- Uterine artery

L7: Anatomy of the perineum

1. **Superficial boundaries of the perineum:**
    a. Anteriorly: Scrotum & Mons pubis
    b. Posteriorly: Buttocks
    c. Lateral: Upper part of the medial thigh

2. **Deep boundaries of the perineum:**
    Same boundaries as pelvic outlet.

3. **Divisions of the perineum:**
    a. Urogenital triangle (anterior).
    b. Anal triangle (posterior).
    c. Transverse line through ischial tuberosities separates the two.

4. **Anal sphincters:**

    A. **Internal anal sphincter:**
    a. Smooth muscle (involuntary)
    b. Upper ¾ of anal canal
    c. Sympathetic supply

    B. **External anal sphincter:**
    a. Striated muscle
    b. Spans entire length of anal canal (voluntary)
    c. Inferior branch of pudendal nerve

5. **Ischioanal fossa**
    a. Wedge shaped fat filled space situated on either side of the anal canal
    b. Boundaries
        i. Floor: Skin.
        ii. Apex: Levator ani and obturator internus fascial meeting.
        iii. Medial: External anal sphincter and levator ani.
        iv. Lateral: Obturator internus muscles, contains pudendal canal.

    c. 2 spaces that are separated by perianal fascia
        i. Perianal space (infection here is very painful due to tension caused by swelling)
        ii. Ischioanal space (infection here is less painful)

Contents:

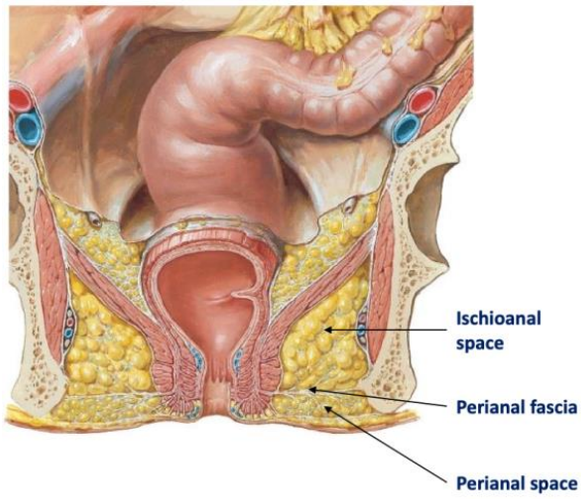

- Fat
- Inferior rectal nerve and vessels
    - Branches of pudendal nerve and artery entering perineum through pudendal canal.
    - They cross the ischioanal fossa laterally to medially.
    - Inferior rectal nerve supplies the external anal sphincter and damage to it can lead to rectal incontinence.
- Posterior scrotal / labial nerves and vessels
- Perineal branch of S4

Note: Abscess formation in the fossa is common due to low vascularity. Abscess can spread from one side of the fossa to the other.

6. **Perineal body**
    a. Nine muscles converge into it
    b. Acts as an anchor for the attached perineal muscles
    c. A tear in the perineal body during vaginal delivery → prolapse of uterus, bladder, or rectum

7. **Urogenital triangle**
    a. **Layers**
        i. Skin
        ii. Superficial fascia
        iii. Colles' fascia: continuous anteriorly with dartos muscle of scrotom, superficial fascia of penis, and anterior abdominal wall
        iv. Perineal membrane
        v. Endopelvic fascia

    b. **Contains 2 perineal pouches**
        i. Deep pouch: between perineal membrane and endopelvic fascia
        ii. Superficial pouch: between colles' fascia and perineal membrane

    c. **Any fluid in the superficial perineal pouch can continue anteriorly into:**
        i. The scrotum (between dartos muscle layer & external spermatic fascia)
        ii. The penis (between superficial & deep fascia)
        iii. Anterior abdominal wall (between the superficial fascia & external oblique aponeurosis)

This is due to the nature of colles' fascia (see above). A common cause is the rupture of the urethra at the bulb of the penis and accumulation of urine in the fashion mentioned above

Contents of the superficial perineal pouch	Contents of the deep perineal pouch
1. Root of the penis, made up of two crura and one bulb (the bulb is traversed by the urethra) 2. Greater vestibular glands in females & ducts of the bulbourethral glands in males 3. Muscles-Ischiocavernosus, Bulbospongiosus & superficial transverse perinei 4. Nerves & Vessels Muscular branches, posterior scrotal & nerve to bulb from pudendal nerve. Branches of internal pudendal artery (perineal artery & artery of the penis)	1. Membranous urethra 2. Bulbourethral glands in males 3. Muscles- External urethral sphincter surrounding the membranous urethra , Deep transverse perinei 4. Nerves & vessels Muscular branches & dorsal nerve of the penis (branches of pudendal nerve) Branches of internal pudendal artery (artery of the penis & its branches)

8. **Pudendal nerve (S2, S3, S4)**
    a. Branch from sacral plexus
    b. Main nerve supplying the perineum and external genitalia
    c. **Course:**
        i. Leaves pelvis via greater sciatic foramen
        ii. Winds around ischial spine
        iii. Enters pudendal canal (and therefore perineum) via the lesser sciatic foramen
        iv. Crosses the ischioanal fossa from lateral to medial
    d. **Branches:**
        i. Inferior rectal nerve: supplies external anal sphincter
        ii. Perineal nerve: divides into posterior scrotal (or labial) and muscular branches supplying perineal muscle. The muscular branch supplies bulbospongiosus and urethra.
        iii. Dorsal nerve of penis: supplies skin of body of penis and glans penis.
    e. **Pudendal nerve block**
        i. Useful in vaginal deliveries.
        ii. Hand is guided into the vaginal until the ischial spine is felt and then the injection is given close to the sacrospinous ligament while the hand remains in place to protect the head of the baby.
    f. **Muscles of superficial perineal pouch**
        i. Ischiocavernosus: maintains penis erection in males, covers crus clitoris in females
        ii. Bulbospongiosus: compresses the deep dorsal vein of the penis, which is required to maintain erection in males. It helps in ejecting last drop of urine at the end of micturition in males, and covers bulb of vestibule in females
    g. **Muscles of deep perineal pouch**
        i. **External urethral sphincter: voluntarily holds urine**
        ii. **Deep transverse perinei**

L8: The Breast

Embryology:

- Belongs to integumentary originally but it is functionally part of reproductive system
- Ectodermal origin.

- Feed babies through modified apocrine sweat glands where the apex of cell becomes part of secretion and breaks off.

Parts:

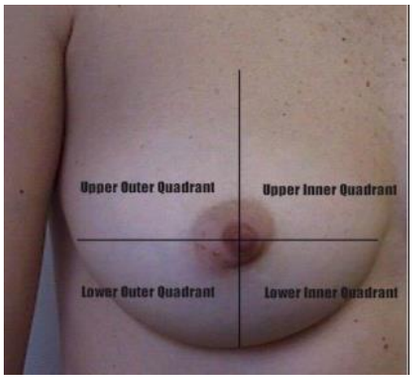

- The shape and size depends upon genetic, racial, dietary factors, age, parity, and menopausal status of the individual (most size differences due to fatty tissue).
- Divided into 4 quadrants.
- Nipples usually at 4th intercostal space.
- Surrounded by areola (pigmented ring of skin that contains melanocytes that intensify with pregnancy, also contains smooth muscle fibers for nipple erection).
- Types:
  - Everted (most common one)
  - Flat
  - Inverted
  - Semi- inverted
  - Wide
- Note: the nipple is a thin skinned region lacking in hair and sweat glands, but it has glands of Montgomery, which are sebaceous glands in the areola giving it a grainy appearance.
- The glands make oily secretions (lipoid fluid) to keep the areola and the nipple lubricated and protected.
- Most breast tissue is usually localized to its upper outer quadrant and it is often implicated in breast cancer and in most benign lesions of breast tissue (site of about 50% of all breast cancers)
- This is because of the presence of the "Tail of Spence", or axillary tail.
  Clinical significance: May be mistaken for axillary lymph nodes.

Attachment:

- Within the thoracic wall btw ribs 2-6, extending from the sternum to the axilla, the breast rests on the deep fascia covering the pectoralis major and is surrounded by superficial fascia that has a superficial and a thicker deep layer.
  Clinical significance: The superficial layer lies immediately beneath the dermis and enables skin flaps to be dissected from the glandular mass of the breast quickly, neatly, and in a relatively avascular plane.
- It is fixed to the skin through & underlying superficial fascia by fibrous C.T bands called suspensory ligaments. (aka coopers ligaments)
  Clinical significance: Contraction of this tissue by malignant infiltration results in the characteristic skin dimpling over a carcinoma.
- Between the deep layer of the superficial fascia and the deep fascia of the pectoralis major there is a layer of areolar tissue that allows the breast to move freely on the underlying fascial covering of the pectoralis major.
- The areolar layer forms the retromammary space/ Sub-mammary space.
  Clinical significance: Precise establishment of the plane of the retromammary space enables rapid and relatively blood-less dissection of the deep aspect of the breast in simple mastectomy.
- The breasts are asymmetrical where the left is usually larger.
- Each breast consists of 15 ~ 20 lobes of secretory tissue where each lobe has one lactiferous duct.
- Each lobe is composed of lobules comprised of alveoli and each alveolus consists of secretory epithelial cells surrounded by myoepithelial cells.

The breast parenchyma is made of: alveoli → lobules → lobes which are surrounded by fibrous stroma and fat.
In the alveolus, secretory epithelium changes with: hormonal signals, onset of menstruation, pregnancy (glands begin to enlarge at 2nd month), and after birth.
The first secretion is called the colostrom (contains many antibodies)

Fatty tissue: surrounds surface, fills spaces between lobes and mainly determines the form & size of breast. (there is no fatty deposit under nipple & areola)

Histology of breast:

- The connective tissue stroma which surrounds the lobes is dense and fibro-collagenous, whereas connective tissue between lobules has a loose texture, which allows the rapid expansion of secretory tissue during pregnancy.
- The interlobar stroma contains variable amounts of adipose tissue, which contributes largely to the increase in breast size at puberty.
- In the lactating breast, the milk is produced in milk producing cells (glandular epithelium) and it continuously comes down the ducts and collects in the lactiferous sinuses.
- Lactiferous sinuses are dilated lactiferous ducts under the nipple which store milk.
- Ducts become contracted again at base of the nipple.
- When the cells are stimulated, they expel additional milk into the duct system (milk ejection reflex).

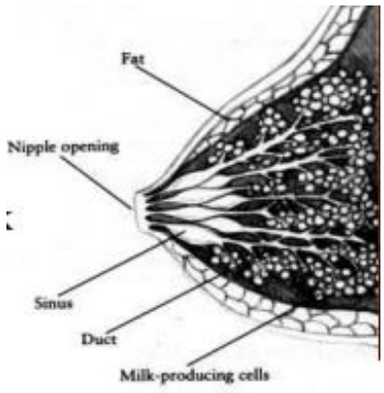

Blood supply of the breast:

- Three supplies:
- Axillary arteries continuous with subclavian artery gives rise to external mammary (or lateral thoracic artery). Supply 30% of the breast.
- Superior thoracic and the pectoral branches of the thoraco-acromial artery also provide some supply.
- Internal mammary (thoracic) arteries are the main supply (60%). Coming as the first descending branch of subclavian artery it supplies intercostal spaces & the breast. **Clinical significance: It is often used as a graft for coronary bypass surgery.**
- Intercostal arteries: numerous branches from internal & external mammary arteries supplying intercostal spaces & breast.

Veins draining the breast:

- Begins as a ring around the base of the nipple called the circulus venosus.
- Large veins passing from the circulus venosus to circumference of mammary gland, then to the external mammary (lateral thoracic) vein → drains into axillary vein (primarily) or to the

internal mammary vein → eventually both going to the subclavian vein and ultimately into the SVC.

Innervation of the breast:

- Anterior & lateral cutaneous nerves of thorax from spinal segments T3 – T6
- Nerves in close proximity: long thoracic nerve (for serratus anterior), thoracodorsal nerve (for latissimus dorsi), intercostalbrachial nerve (lateral cutaneous nerve sensory to medial arm & axilla), and the medial and lateral pectoral nerves for the pectoralis major and minor. **Clinical significance: are important to visualize as they cross through the anatomic spaces of the breast and axilla and are thus important to consider during surgical dissection.**

Lymphatic drainage of the breast:

- This is of considerable importance in the spread of breast cancer.
- Lymph drainage follows the blood supply.
- There is a tendency for the lateral part of the breast to drain towards the axilla and the medial part to the internal mammary chain.
- **Lateral quadrants** drain to the anterior axillary nodes (pectoral nodes) → central axillary nodes → apical nodes → deep cervical nodes → sub-clavicular (subclavian) nodes.
- **Medial quadrants** drain into parasternal nodes
- **Superficial regions** of skin, areola, nipples form large channels & drain into pectoral nodes (anterior axillary).
- Rotter's nodes are nodes between pectoralis minor and major muscles
- Internal mammary chain (relatively minimal drainage)
- The axillary lymph nodes are 5 groups: anterior, posterior, lateral, central, apical.
- Clinicians and pathologists often define metastatic axillary node spread simply into three levels:

    1. Level I – lateral to pectoralis minor
    2. Level II – along & under pectoralis minor
    3. Level III - medial to pectoralis minor

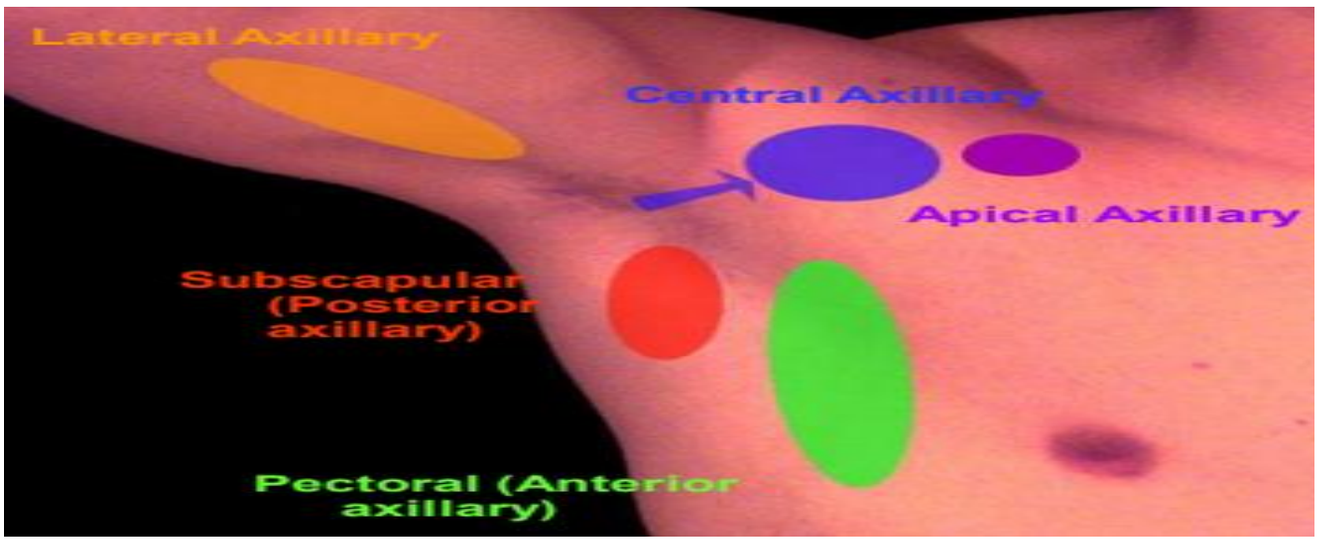

Developmental abnormalities of breast:

- Inverted nipple which is when the nipple fails to evert. (congenital or due to cancer)
- Ectopic nipple: polythelia or hyperthelia. Additional nipples along the milk line (supernumerary nipples). More common than supernumerary breast. May darken during pregnancy.
- Amastia: breast on one or both sides, may be small or even absent
- Micromastia
- Macromastia
- Gynecomastia: breast development of male in areolar region (noted in males who smoke marijuana at puberty)